



OCEAN WE ARE FOUNDATION  
WILDCRAFT  
#AW\$OME



**DR. BRA INSTITUTE ROTARY CANCER HOSPITAL  
ALL INDIA INSTITUTE OF MEDICAL SCIENCES  
ANSARI NAGAR, NEW DELHI-110029**

Ref. No.F.1/IRCH/MR/2025-2026

Dated 30 APRIL 2025

**ESTIMATE CERTIFICATE**  
**TO WHOM IT MAY CONCERN**

This is to certify that Miss. Risha Kumari , Age 07 years, Female, D/o Mr.Raju Sah , (UHID-10679280 & IRCH No. 300656/23) is a known case of **Neuroblastoma** and is under treatment with Medical Oncology at DR. BRA IRCH, AIIMS since 24.07.2023.

The approximate cost for her treatment would be Rs. 5,00,000/- (Rupees Five Lakhs Only).  
The item-wise breakup of the expenditure is as under:-

S.No.	Name of Medicines with dosage/Consumables Required for treatment/operation	Duration of treatment	Approx. cost	Name of Procedure
1.	Conditioning regimen	1 week	Rs. 1,00,000/-	
2.	Stem cell harvest	1 week	Rs. 2,00,000/-	
3.	Post transplant supportive care	03 Months	Rs. 2,00,000/-	
<b>Total approximate cost of the treatment</b>			<b>Rs. 5,00,000/-</b>	


The cheque/draft may be sent in favour of "DR. BRA IRCH, AIIMS, Ansari Nagar, New Delhi-29 (IRCH Patient Treatment Account)"

(NB: This estimate certificate is valid for six months from the date of issue)

**OCEAN WELFARE FOUNDATION**  
LET'S MAKE A CHANGE TOGETHER



**(COUNTER SIGNED BY HOD)**

  
**(SIGNATURE BY CONSULTANT)**

आचार्य समीर बख्शी / Prof. SAMEER BAKHSI  
आचार्य एवं शिक्षक/Professor & Head  
ऑन्कोलाजी अस्पताल विभाग/Dept. of Medical Oncology  
डी. बी.आर.ए., आर.आर.सी.एच., अ.भा.आ.सं., नई दिल्ली-29  
Dr. B.R.A. I.R.C.H., A.I.I.M.S., New Delhi-29  
पंजीयन संख्या/Reg. No. 18936

  
**(COUNTER SIGNED BY M.S)**

चिकित्सा अधीक्षक/MEDICAL SUPERINTENDENT  
अ.भा.आ.सं. अस्पताल/A.I.I.M.S. HOSPITAL  
डी. बी.आ.सं. अ.भा.आ.सं./Dr. B.R.A., I.R.C.H.  
नई दिल्ली-110029/New Delhi-110029



**ALL INDIA INSTITUTE OF MEDICAL SCIENCES**  
 Department of Nuclear Medicine  
 Ansari Nagar, New Delhi-110029

Tel : 91-11-26588111-6593245

**Physician Details**

DR. B.R.A. BHALLA, NEW DELHI

Reg. Date-12/03/2025

Clinic No. 2025/23431

ICCH No. 100656

Centre: Radioisotope & Leukemia Clinic

Deptt. MEDICAL ONCOLOGY

General

डॉ. रिया कुमारी

Name: RISHA KUMARI

City: GAZIABAD

Phone No. 7780016955

Address: SARARI, BIHAR, Pin-0, INDIA

Positron Emission Tomography (PET) Scan form is not properly filled)

Yrs \_\_\_\_\_ Sex \_\_\_\_\_ M \_\_\_\_\_ F \_\_\_\_\_

Acquisition Date : \_\_\_\_\_

UHID-106792980

Sex/Age: F / 8Y

Room: 1 (Shift: Afternoon)

Signature  Previous Malignancies

Investigation:

Bid Sugar: \_\_\_\_\_ Fasting \_\_\_\_\_ pp \_\_\_\_\_ Random \_\_\_\_\_ Date: \_\_\_\_\_


Ultrasound/ECHO: \_\_\_\_\_

CT/MRI/Plain/Contrast: \_\_\_\_\_

Previous Nuclear Medicine/PET: \_\_\_\_\_

Treatment History: \_\_\_\_\_

Desired Study:  Whole Body PET (NECK to mid thigh)  Brain only  Cardiac only



Instructions to patients:

1. Please bring DD/Pay Order for Rs. 5000/- 7500/- in favour of "DIRECTOR AIMS" and write name of patient on reverse DD with date of scan. Payment is to be made on the day of the test.
2. No food after midnight if study is scheduled before 1 p.m.
3. No food after 7 a.m. if study is scheduled after 1 p.m. (Patient may eat light breakfast before 7 a.m.)
4. Must bring all old records.
5. Study is subject to availability of RADIOISOTOPE
6. Report shall be available 24-48 hrs. after test.
7. No CD will be given

Appointment Date: \_\_\_\_\_ Time: \_\_\_\_\_

Payment: W Body \_\_\_\_\_ Cardiac \_\_\_\_\_ Brain \_\_\_\_\_

Receipt No/DD No. \_\_\_\_\_ Amount \_\_\_\_\_ Lit. \_\_\_\_\_ drawn on \_\_\_\_\_



OCEAN WELFARE FOUNDATION

LET'S MAKE A CHANGE TOGETHER

जन्म तिथि / DOB 01/01/1989

सल्लाह / फिर्मा



3447 0 [REDACTED] 1

आधार - आम आदमी का अधिकार



भारत सरकार  
Government of India



Aadhaar no. is sued: 18/11/2018



रिशा कुमारी  
Risha Kumari  
जन्म तिथि/DOB: 01/10/2016  
महिला/ FEMALE

आधार पहचान का प्रमाण है, नागरिकता या जन्मतिथि का नहीं।  
इसका उपयोग सत्यापन (ऑनलाइन प्रमाणीकरण, या क्यूआर कोड/  
ऑफलाइन एक्सएमएल को स्कैनिंग) के साथ किया जाना चाहिए।

**Aadhaar is proof of identity, not of citizenship  
or date of birth. It should be used with verification (online  
authentication or scanning of QR code / offline XML).**

OCEAN WELFARE FOUNDATION  
LET'S MAKE A CHANGE TOGETHER

6619 2 [REDACTED] 5

मेरा आधार, मेरी पहचान



डा. बी. आर. अम्बेडकर संस्थान रोटरी कैंसर अस्पताल  
 Dr. B.R. Ambedkar Institute Rotary Cancer Hospital  
 अ.भा.आ.सं. अस्पताल/A.I.I.M.S. HOSPITAL  
 बहिरंग रोगी विभाग / Out Patient Department  
 अस्पताल के अन्दर धूम्रपान मना है / SMOKING PROHIBITED IN HOSPITAL PREMISES

OPR-6

एकम / One

IRCH No.

DR. B.R.A. IRCH, AIIMS, NEW DELHI

वि IRCH No. 300656

Reg. Date-12/03/2025

वि. पंजीकृत सं./O.P.D. Regn. No.

Clinic Paed. Lymphoma Leukemia Clinic  
 Deptt. MEDICAL ONCOLOGY  
 General

Clinic No. 2025//23431



आयु  
Age

जन्म तिथि / Date of Birth

नाम रिशा कुमारी

UHID-106792980

106792980

Name RISHA KUMARI

D.O-RAJU SAH

Sex/Age F/8Y  
 Room 1 (Shift Afternoon)

IRCH

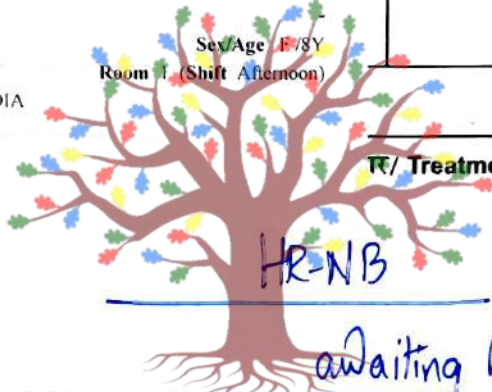
Phone No. 7780016955

IR/ Treatment

Address SARARI, BIHAR, Pin-0, INDIA

Paid Online

वि



awaiting ASCT.

OCEAN WELFARE FOUNDATION  
 LET'S MAKE A CHANGE TOGETHER  
 on OMT.

Repeat PET scan: s/o progressive disease.

Advice:

- ~~C~~ Thalidomide 50mg hs. (फिर) (फोटा 12)
  - C Celecoxib 100mg BD. (फिर मात्र 3 एफएनए)
  - C Etoposide 50mg OD x 3 weeks to alternate with
  - ~~T~~ Endoxan 50mg OD x 3 weeks. (फिर मात्र 3 एफए)

N/V: 8/8/2025 C CBC and PET scan repeat.

अंगदान-जीवन का बहुमूल्य उपहार / ORGAN DONATION-A GIFT OF LIFE

O.R.B.O., AIIMS, 26588360, 26593444, www.orbo.org Helpline-1060 (24 hrs.service)

बाहर से आने वाले रोगियों के लिए धर्मशाला की सुविधा उपलब्ध है / Dharamshala facility is available for outstation patients

3. CDER dental review. (Dental Builder)

*Amiana SR.*

22/2/19  
 9/5/25  
 Mon/  
 Wed/  
 Fri  
 10/5/25  
 9/5/25

रिजिस्ट्रेशन कने जारी किया  
 IRCH Concession Issue Dt  
 डॉ. बी. आर. अ. सं., अ. भा. आ. सं., नई दिल्ली-20  
 Dr BRA IRCH AIIMS New Delhi 20  
 9/5/25

7838926783 गोपिया

7339503118 - पोयल

T. 85/24-25

7339503118



डॉ. बी. आर. अम्बेडकर संस्थान रोटरी कैंसर अस्पताल

Institute Rotary Cancer Hospital / A.I.I.M.S. Hospital

OPR-6

IRCH No. 190656  
Clinic Bone Marrow Transplant Clinic  
Dept. MEDICAL ONCOLOGY

Reg Date-23/02/2024  
Clinic No. 2024/1925



UHID-106792980

नाम रिषा कुमारी  
Name RISHA KUMARI  
D/O- RAJUSAH  
Phone No. 7780016955  
Address SARARI, BIHAR, Pin 0, INDIA

Sex/Age F/17  
Room 7 (Shift Afternoon)

प. 300656

वैद्यकीय परीक्षा सं/O.P.D. Regn. No.

लिंग/प्रा. Sex	आयु Age	जन्म तिथि / Date of Birth
F/Yr	F	

DR. B.R.A. IRCH/AIIMS, NEW DELHI

निदान / Diagnosis

Abis:--HR; Nb [NMYC<sup>+</sup>];--JNR655-M

दिनांक / Date

-: 23/1/2024 :-

उपचार / Treatment

Adv:- Francis arranged

- To plan early mobilisation
- Next t/o 27/1/24.



railway pass

Niranjan Singh  
Srinivas

22/1/24  
Dr. B.R.A. IRCH AIIMS New Delhi

वरिष्ठ रजिडेंट / SENIOR RESIDENT  
डिपार्टमेंट ऑफ मेडिकल ऑन्कोलॉजी  
डॉ. बी. आर. अम्बेडकर संस्थान, रोटरी कैंसर अस्पताल, नई दिल्ली-29

27/1/24

- cap Thelidomide 50 mg OD HS.
- cap celecoxib. 100 mg BD.
- cap Etoposide 50 mg OD M/W/F. x 3 wk
- ↓ STOP
- Tab Endoxan 50 mg OD M/W/F next 3 wk
- NO do harvest on priority.

lt- 22/1/24

अंगदान-जीवन का बहुमूल्य उपहार / ORGAN DONATION - A GIFT OF LIFE

O.R.B.O.AIIMS, 26588360, 26593444, www.orbo.org Helpline-1060 (24 hrs. service)

बाहर से आने वाले रोगियों के लिए धर्मशाला की सुविधा उपलब्ध है / Dharamshala facility is available for outstation patients

- Plv on 24/1/2025 E.C.E.I.M.T.R.S.

Dr. DEBARAJA MOHAPATRA  
MD, DM (Pediatric Oncology)  
BMT Fellow/Medical Oncology  
AIIMS, New Delhi



ACE Scanner



अ० भा० आ० सं० अस्पताल / A.I.I.M.S. HOSPITAL  
बहिरंग रोगी विभाग / Out Patient Department



अस्पताल के अन्दर धूम्रपान मना है। / SMOKING IS PROHIBITED IN HOSPITAL PREMISES

सर्जरी.

UHID: 108019616  
ABHA: 2010\_rani@abdm  
Dept No: 20240070045048

कमरा / Room 15

Queue / संख्या F16  
Unit-IV, Surgery

OPR-6

रानी कुमारी / RANI KUMARI

D/O RAJU SAH  
15Y 2M 12D / F (महिला)  
BHAR, BHAR, Pin-0, INDIA

Ph: 7780016955 General Rs 0  
Follow Up Patient



कोरोनिक पंजीकृत सं०/O.P.D. Regn. No.

आयु  
Age

पता/Address

108019616  
SUN

निदान/Diagnosis

दिनांक/Date

उपचार/Treatment

flulid traumatic ulcer over  
Right thigh (1st)  
also severe itching  
and body discharge.

OCEAN WELFARE FOUNDATION  
LET'S MAKE A CHANGE TOGETHER

Not relieving on medication -  
- No fever spike

Culture -  
Sensitive to  
linezolid.

OLE:-  
Ulceroprotek  
Excoriated heaped elevation  
with Central scar

Adv  
to skin edge  
Bx in minor  
OT (B)  
NBP  
- Refer to Dermat  
~~Refer to Dermat~~

13/3/25  
Smor-19  
ASP + LA  
- skin edges  
of ulcer healed  
- compressive  
dressing done.

Advice  
- Remove dressing  
after 2 days  
- J. flexion BS x 3 dys fls 500  
Review c H/E reports  
after 2 wks  
for ORO

वरिष्ठ रेजीडेंट  
Senior Resident

शल्य चिकित्सा विभाग / Dept. of Surgery  
अ० भा० आ० सं० दिल्ली / A.I.I.M.S., New Delhi-110029

flu with reports  
- ointment Mupirocin  
- Lactocubamine lotion



CLEAN AND GREEN AIIMS / एम्मा का पत्थर सफल, स्वच्छता से काया कल्प  
भगदान-जीवन का बहुमूल्य उपहार / ORGAN DONATION - A GIFT OF LIFE  
O.R.B.O., AIIMS, 26588360, 26593444, www.orbo.org Helpline - 1060 (24 hrs service)



13/3/2025



डा. बी. आर. अम्बेडकर संस्थान रोटरी कैंसर अस्पताल  
**Dr. B.R. Ambedkar Institute Rotary Cancer Hospital**  
**A.I.I.M.S. HOSPITAL**

OPR-6

DR. B.R. A. IRCH, AIIMS, NEW DELHI

Reg. Date-14/02/2025

Clinic No. 2024/1325



UHID-106792980

Out Patient Department  
 NO. SMOKING PROHIBITED IN HOSPITAL PREMISES

IRCH No. 300656

Clinic Bone Marrow Transplant Clinic

Deptt. MEDICAL ONCOLOGY

General

नाम रिषा कुमारी

Name RISHA KUMARI

D/O- RAJU SAH

Phone No. 7780016955

Address SARARI BIHAR, Pin 0, INDIA

Paid Online

ब०रो०वि० पंजीकृत सं०/O.P.D. Regn. No.

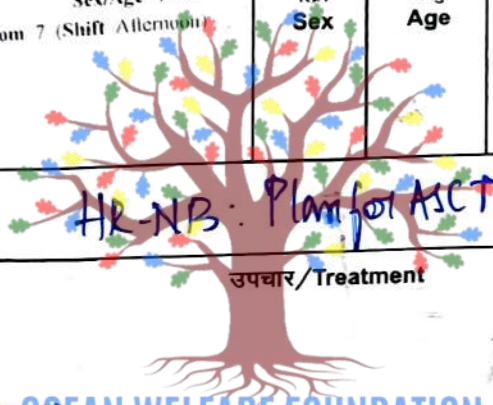
Sex/Age 1/8Y  
 Room 7 (Shift Afternoon)

लिंग  
Sex

आयु  
Age

जन्म तिथि/Date of Birth

निदान/Diagnosis



दिनांक/Date

उपचार/Treatment

Plan:

OCEAN WELFARE FOUNDATION  
 LET'S MAKE A CHANGE TOGETHER

1. PET-CT
2. BMA+B/L BMBx date
3. N/V 28/3/25

Dated on  
 17/3/25  
 @ 8:30am

13/3/25 Informa/SR.  
 Dr. B.R. Ambedkar Institute Rotary Cancer Hospital  
 Dr. B.R.A. IRCH, AIIMS, New Delhi-25

6-22-81g

17/3/25

Adverse

Post BMA + Bopsy - persistent pain

Syrup PCM (5/25) - 5.5 ml BD x 3 days  
 TDS x 2 days

weight  
 18kg

#b  
 SOS  
 Deepen  
 Sino

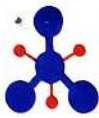
अंगदान-जीवन का बहुमूल्य उपहार/ORGAN DONATION - A GIFT OF LIFE

O.R.B.O., AIIMS, 26588360, 26593444, www.orbo.org Helpline - 1060 (24 hrs service)

बाहर से आने वाले रोगियों के लिए धर्मशाला की सुविधा उपलब्ध है/Dharamshala facility is available for outstation patients







Accession No.	162414640	Registration Date	: 29/03/2025 09:31:50
Patient ID	P16100013921	Sex / Age	: Female 8 Yrs
Patient Name	Baby RISHA KUMARI	Report Released on	: 29/03/2025 11:21:22
Client Name	CANKIDS	Aadhar/ Passport No	:
Ref. By	Mr. CANKIDS		

**DIGITAL WHOLE BODY PET CT**

**Clinical History: Known case of neuroblastoma with diffuse metastasis. Post chemotherapy (till Feb 2024). On oral chemotherapy. PET/CT study for further evaluation.**

**Procedure:** 6.0 mCi of <sup>18</sup>F-fluorodeoxyglucose was administered intravenously. To allow for distribution and uptake of radiotracer, the patient was allowed to rest quietly for 60 minutes in a shielded room. Imaging was performed on an integrated PET/CT scanner. CT images for attenuation correction and anatomic localization followed by PET images from vertex to toe were obtained. SUVmax was normalized to body weight *SUVmax bw*. Serum Creatinine and blood glucose was 0.30mg/dL and 99mg/dL respectively. CT scanning was performed using non-ionic intravenous and oral contrast. No adverse reaction was observed during the scan.

**Observations:**

**Brain: -**

Normal physiological tracer distribution noted in the brain parenchyma. No focal lesion or abnormal uptake noted in the brain.

*(NOTE: If there is a strong suspicion for brain metastases, then MRI is suggested for further evaluation as small lesions may not be detected on an FDG PET/CT study due to normal high physiological uptake in the brain).*

**Head and Neck: -**

Nasopharynx, oropharynx, hypopharynx and larynx appear normal with no abnormal FDG uptake is seen in relation to them.

*Diffuse symmetrical FDG uptake noted in bilateral tonsils – likely inflammatory.*

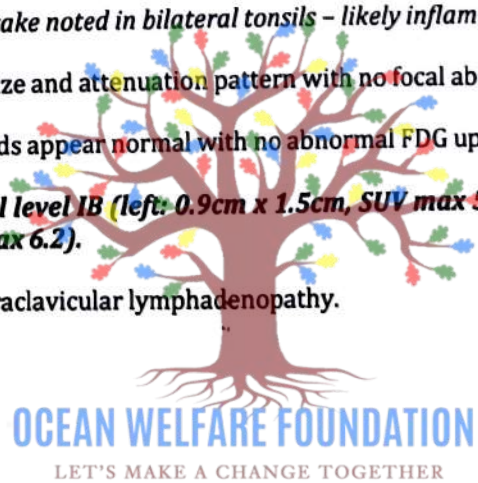Thyroid gland is normal in size and attenuation pattern with no focal abnormal FDG uptake.

Bilateral major salivary glands appear normal with no abnormal FDG uptake.

**FDG avid bilateral cervical level IB (left: 0.9cm x 1.5cm, SUV max 5.2) & II lymph nodes are noted (right level II: 1.1 x 1.0cm, SUV max 6.2).**

No significant FDG avid supraclavicular lymphadenopathy.

**Thorax: -**





Accession No.	162414640	Registration Date	: 29/03/2025 09:31:50
Patient ID	P16100013921	Sex / Age	: Female 8 Yrs
Patient Name	: Baby RISHA KUMARI	Report Released on	: 29/03/2025 11:21:22
Client Name	: CANKIDS	Aadhar/ Passport No	:
Ref. By	: Mr. CANKIDS		

The heart and the mediastinal vascular structures are well opacified with I/V contrast. The trachea and main bronchi appear normal.

*Mildly increased FDG uptake noted in soft tissue density in anterior mediastinum – likely physiological thymic uptake.*

Both lung fields are showing normal attenuation. No focal abnormal FDG uptake is noted in the lung parenchyma.

No obvious pleural thickening/ effusion.

No significant FDG avid mediastinal lymph nodes.

*Non FDG avid subcentimetric bilateral axillary lymph nodes with preserved fatty hilum noted – likely non-specific.*



**Abdomen and Pelvis: -**

Liver parenchyma is normal in attenuation values and enhancement pattern. **Focal FDG avid subtle hypodense area noted in segment VII of liver (SUV max 3.4).** Intrahepatic biliary radicals are not dilated. Portal and hepatic veins are normal.

Gallbladder, pancreas, spleen, adrenals and bilateral kidneys appear unremarkable. (USG is the modality of choice to evaluate for cholelithiasis/choledocholithiasis).

**Mildly FDG avid and non-avid left paraaortic, preaortic, aortocaval and mesenteric (1.8 x 1.5cm, SUV max 2.6) lymph nodes are noted.**

There is no ascites.

The stomach, small and large bowel loops appear normal in calibre and fold patterns and shows physiological FDG uptake.

No abnormally increased FDG uptake noted in relation to the uterus.

**Musculoskeletal: -**

No abnormal FDG uptake noted in axial and visualized appendicular skeleton.



Accession No. : 162414640	Registration Date : 29/03/2025 09:31:50
Patient ID : P16100013921	Sex / Age : Female 8 Yrs
Patient Name : Baby RISHA KUMARI	Report Released on : 29/03/2025 11:21:22
Client Name : CANKIDS	Aadhar/ Passport No :
Ref. By : Mr. CANKIDS	

**OPINION:**

**PET-CT study reveals: -**

- Metabolically active bilateral cervical and abdominal lymph nodes, as described.
- Focal FDG avid subtle hypodense area in segment VII of liver. Close follow up /MRI correlation is advised.
- No other abnormal hypermetabolic focus noted in rest of the visualized body.

No previous FDG PET/CT study is available for comparison.

Clinical and HPE correlation is advised.


This report is not valid for medico-legal purpose.  
In case of any discrepancy due to machine error or typing error, please get it rectified.  
Kindly bring all previous reports and PET- CT CD for follow up PET - CT scans.



\*\*\* End of Report \*\*\*

**Dr Ajiv Mishra**  
MBBS MD ( Nuclear Medicine )  
Consultant Nuclear Medicine  
DMC/R/21180

**Dr S Ramya**  
MBBS MD (Nuclear Medicine)  
Consultant Nuclear Medicine  
DMC Reg No 69751

  
**Dr. Nikunj Jain**  
DRM, DNB, FEBNM,  
FANMB, DIp. CBNC.  
Sr. Consultant & Director  
Molecular Imaging

Page No: 3 of 3

Ghaziabad (U.P.):  
Molecular Diagnostics and Therapy LLP  
Previously Vitrana Healthcare LLP  
Plot No 14 & 15, Block P, Sector 23,  
Sanjay Nagar, Ghaziabad U.P.  
Phone : 0120 4174450

Paschim Vihar (North West Delhi) :  
Plot No. 27, Paschim Vihar Extn.  
Opposite Metro Pillar No. 196  
Phone : 011-69041555



DIAL IMAGING  
☎ 704 292 8881, 704 292 8882

Green Park Extn. (South Delhi) :  
H-2, Basement & Ground Floor,  
Ch. Hukum Chand Marg, New Delhi, 110016  
Phone : 011- 40023830



DIAL PATHLAB  
☎ 931 908 1150, 931 909 7574

Empanelments: CGHS | ESI | DGHS | DAK





अखिल भारतीय आयुर्विज्ञान संस्थान, नई दिल्ली  
ALL INDIA INSTITUTE OF MEDICAL SCIENCES, NEW DELHI  
DEPARTMENT OF PATHOLOGY

Patient Name	: RISHA KUMARI	UHID NO.	: 106792980
Accession No	: S2513917	F/H Name	: D/O RAJU SAH
Age/Sex	: 8Y /Female	Additional ID	: 300656
Clinic/Dept	: IRCH	Unit	: N/A
Consultant Incharge	: Dr. Sameer Bakhshi	Request Date/Time	: 17-03-2025 /11:20:57
		Receiving Date/Time	: 17-03-2025 /15:13:25

### HISTOPATHOLOGY REPORT

#### GROSS EXAMINATION:

Accession No. : S2513917A

Received two pieces of linear cores of bony tissue measuring 2.5 cm.

#### MICROSCOPIC EXAMINATION:

Bone marrow biopsy is adequate and shows a cellularity of 50-60%.

Hematopoietic cells of all three series are seen.

There is no increase in interstitial immature cells/atypical cells/granulomas in the sections examined.

There is no evidence of metastasis in the sections examined.

Note : Patient is a case of HR-Neuroblastoma vide clinical history.

#### DIAGNOSIS:

S2513917A

Bone Marrow

Bone marrow biopsy

• Descriptive, see above

End Report

Reporting Resident: Dr. Shivangi Dagar

Reporting Faculty: Dr. Saumyaranjan Mallick

Reporting Faculty: Dr. Rachana Meena

Reporting Date/Time: 28-03-2025 17:23

#### Disclaimer :

1. This report is electronically generated and does not require a signature or stamp to be considered valid.
2. The pathology diagnosis is to be interpreted by the treating physician in conjunction with clinical features, imaging, and other investigations.



प्रयोगशाला अबुर्द विज्ञान, डॉ भीमराव अम्बेडकर संस्थान रोटरी कैंसर अस्पताल अखिल  
भारतीय आयुर्विज्ञान संस्थान नयी दिल्ली -110029

LABORATORY ONCOLOGY , Dr B.R.A. Institute Rotary Cancer Hospital All India  
Institute of Medical Sciences , New Delhi-110029

UHID: 106792980 Reg Date : 14/06/2023 08:38 AM  
Patient Name : Miss. RISHA KUMARI  
Sex : Female Age : 8 years 5 months 16 days  
Department : Medical Oncology Unit Name : Unit-I  
Unit Incharge : Sample Collection Date: 17/03/2025 11:20 AM  
Lab Name: Lab Oncology Sample Received Date: 18/03/2025 11:19 AM  
Lab Sub Centre: Lab Oncology (IRCH)  
Dept / IRCH No: 300656 Recommended By: Dr. Nikhil Vasudeva IRCH  
Lab Reference No: 994

Sample Details : LOI-170325096-BP (Bone Marrow) / Report Date: 20/03/2025 11:00 AM

BMA BMT PS

**Report:** Cellular bone marrow preparation shows haematopoietic cells of all series (M:E=3.2:1).  
There is no evidence of metastasis in the smears examined.

Peripheral smear is unremarkable.

**Advice :** Correlation with bone marrow biopsy

**Conclusion**

Senior Resident: Dr Komal

Consultant: Dr Amar Ranjan

This is an electronically generated report, authorized signature is not required. The test reports have been authenticated. Partial reproduction of the report is not permitted.

( drkomalirch )

Verified By

Authorized Signatory

\*\*\*\*\*END OF THE REPORT\*\*\*\*\*



UHID: 106792980 Reg Date : 14/06/2023 08:38 AM  
Patient Name : Miss. RISHA KUMARI  
Sex : Female Age : 8 years 5 months 16 days  
Department : Medical Oncology Unit Name : Unit-I  
Unit Incharge : Sample Collection Date: 17/03/2025 11:20 AM  
Lab Name: Lab Oncology Sample Received Date: 18/03/2025 11:19 AM  
Lab Sub Centre: Lab Oncology (IRCH)  
Dept / IRCH No: 300656 Recommended By: Dr. Nikhil Vasudeva IRCH  
Lab Reference No: 994

Sample Details : LOI-170325096-BP (Bone Marrow) / Report Date: 20/03/2025 11:00 AM

BMA BMT PS

Report: Cellular bone marrow preparation shows haematopoietic cells of all series (M:E=3.2:1).

There is no evidence of metastasis in the smears examined.

Penpheral smear is unremarkable.

Advice : Correlation with bone marrow biopsy

LET'S MAKE A CHANGE TOGETHER

Conclusion

Senior Resident: Dr Komal

Consultant: Dr Amar Ranjan

This is an electronically generated report, authorized signature is not required. The test reports have been authenticated. Partial reproduction of the report is not permitted.

( drkomalirch )

Verified By

Authorized Signatory

\*\*\*\*\*END OF THE REPORT\*\*\*\*\*



अखिल भारतीय आयुर्विज्ञान संस्थान, नई दिल्ली  
ALL INDIA INSTITUTE OF MEDICAL SCIENCES, NEW DELHI  
DEPARTMENT OF PATHOLOGY

Patient Name : **RISHA KUMARI** UHID NO. : **106792980**  
Accession No : **S2513917** F/H Name : **D/O RAJU SAH**  
Age Sex : **8Y /Female** Additional ID : **300656**  
Clinic Dept : **IRCH** Unit : **N/A**  
Consultant Incharge : **Dr. Sameer Bakhshi** Request Date/Time : **17-03-2025 /11:20:57**  
Receiving Date/Time : **17-03-2025 /15:13:25**

**HISTOPATHOLOGY REPORT**

**GROSS EXAMINATION:**

Accession No. : **S2513917A**

Received two pieces of linear cores of bony tissue measuring 2.5 cm.

**MICROSCOPIC EXAMINATION:**

Bone marrow biopsy is adequate and shows a cellularity of 50-60%.

Hematopoietic cells of all three series are seen.

**OCEAN WELFARE FOUNDATION**  
LET'S MAKE A CHANGE TOGETHER

There is no increase in interstitial immature cells/atypical cells/granulomas in the sections examined.

There is no evidence of metastasis in the sections examined.

Note : Patient is a case of HR-Neuroblastoma vide clinical history.

**DIAGNOSIS:**

S2513917A Bone Marrow Bone marrow biopsy • Descriptive, see above

End Report

Reporting Resident: Dr. Shivangi Dagar

Reporting Faculty: Dr. Saumyaranjan Mallick

Reporting Faculty: Dr. Rachana Meena

Reporting Date/Time: 28-03-2025 17:23

**Disclaimer :**

1. This report is electronically generated and does not require a signature or stamp to be considered valid.
2. The pathology diagnosis is to be interpreted by the treating physician in conjunction with clinical features, imaging, and other investigations.